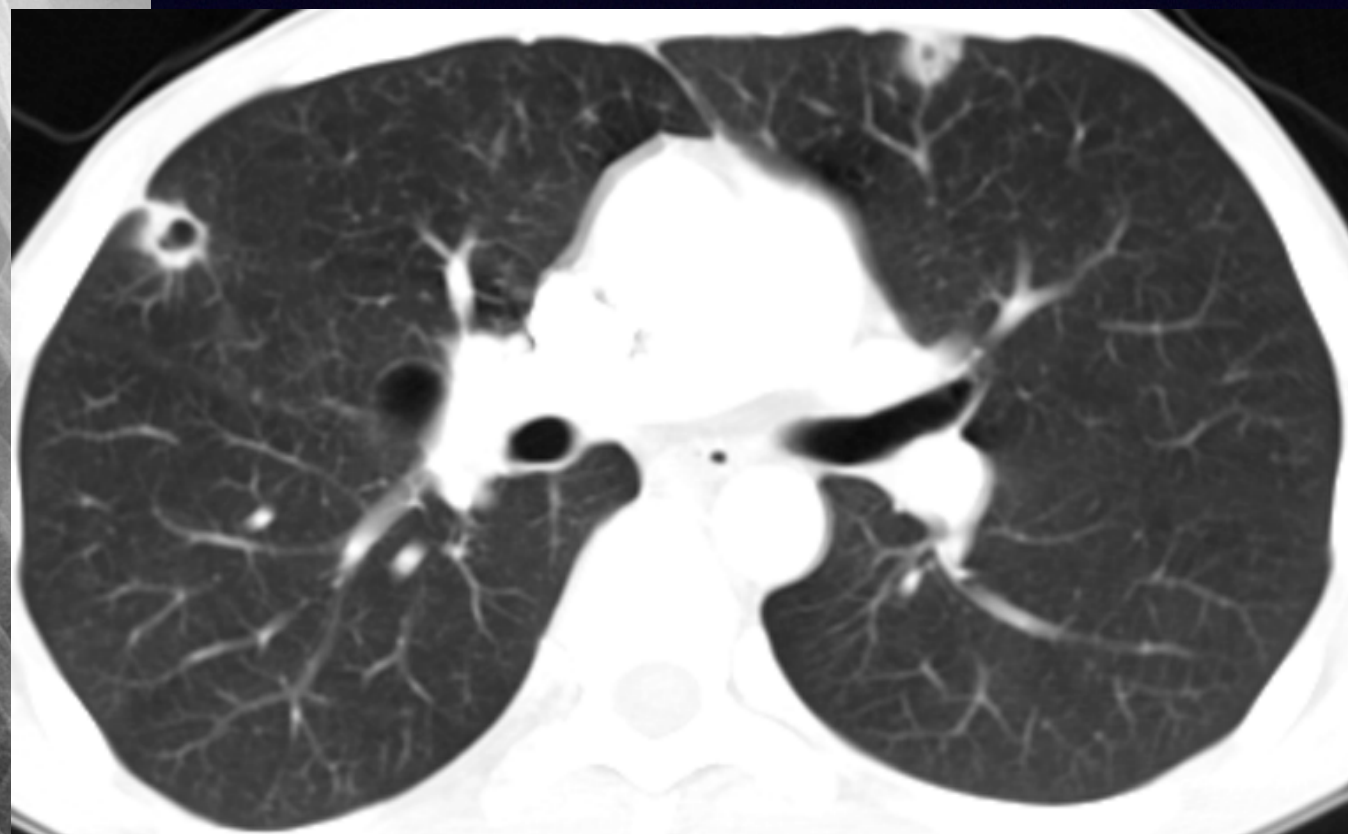
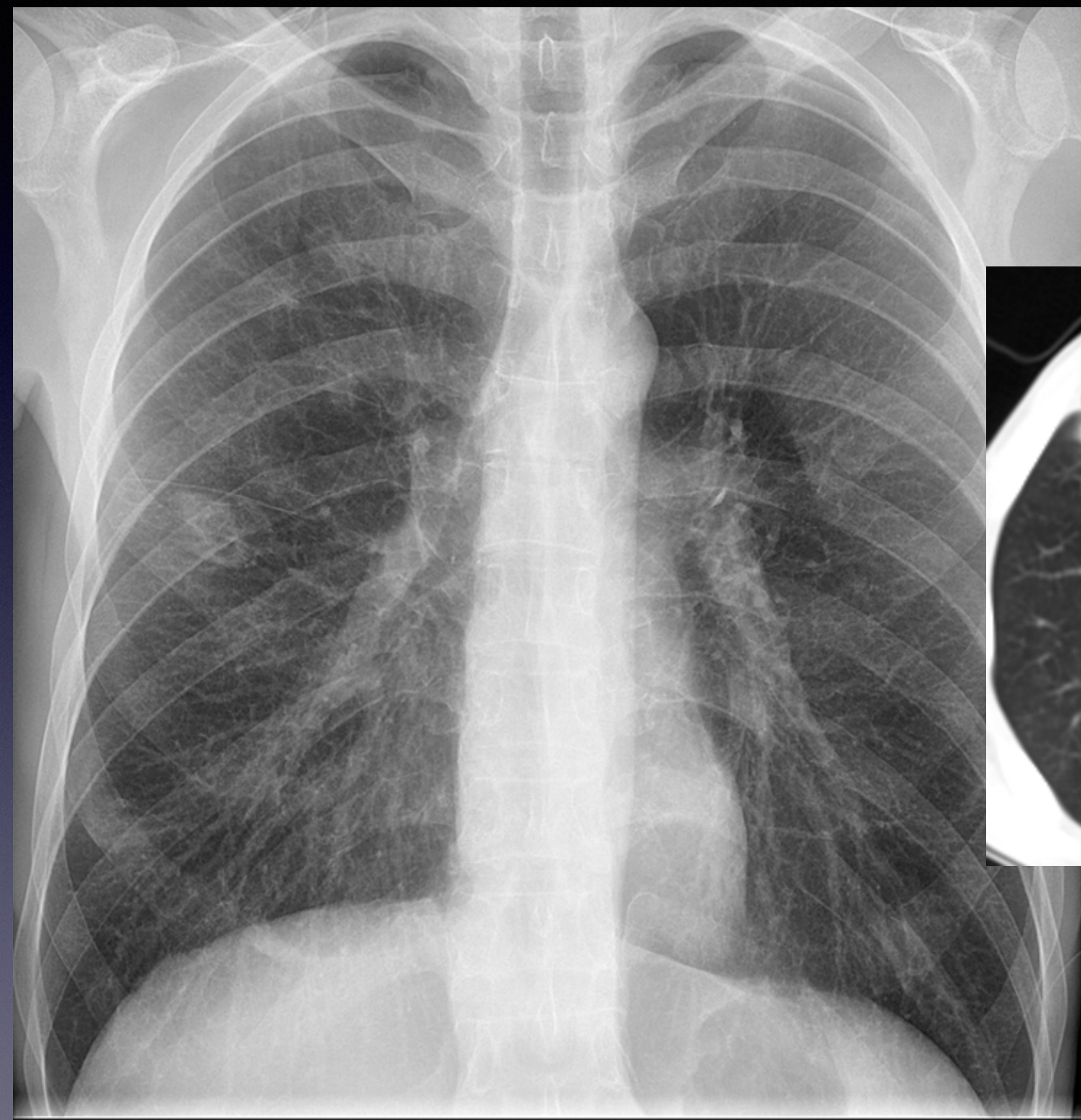


Case 19



@TanMohammedMD

Case 19 Questions

- What is a possible etiology for these imaging findings?
- What is the sign depicted on the CT image?
- What is the treatment for this diagnosis?



@TanMohammedMD

Case Response Policy

Please DO NOT post ANSWERS or SPOILERS

Reply ONLY with professionally appropriate comments or GIFs

- Medical education should be fun and interactive
- It requires professionalism and respect for patients and their families at all times
- If any responses are deemed inappropriate, you may be DM'd with a request to remove your tweet
- Lack of compliance may result in blocking participants temporarily or permanently

Please note this policy will allow us to safely share cases on social media



@TanMohammedMD